

Correspondence

AIDS 2003, 17:445–453

Effect of co-formulated zidovudine, lamivudine and abacavir (Trizivir) on antiretroviral-naive patients presenting with advanced HIV-1 infection

Co-formulated zidovudine, lamivudine and abacavir was used in seven therapy-naive patients with advanced HIV-1 (four mycobacterial infection, two *Pneumocystis*, one lymphoma). The median viral load was 180 000 copies/mm³ and the median CD4 cell count was 27 cells/mm³. All achieved viral loads of less than 80 copies/ml by week 24 and survived beyond 48 weeks. Six had sustained viral suppression over 12–18 months and CD4 cell increases were 198 cells/mm³ (111–308 cells/mm³) supporting the use of this combination in patients with advanced disease.

Concern over toxicity and adherence to antiretroviral therapy and drug–drug interactions has led to the development of simpler antiretroviral regimes including the triple nucleoside combination of zidovudine, lamivudine and abacavir. The simplification of protease inhibitor-based therapy with the triple nucleoside combination has been demonstrated to improve serum lipids significantly and ease dosing regimes [1,2]. In therapy-naive patients triple nucleoside therapy appears to be well tolerated and adherence is enhanced [3,4]. In an observational study of 108 therapy-naive, incarcerated patients without AIDS and with CD4 cell counts greater than 50 cells/mm³, directly observed therapy with combivir (lamivudine and zidovudine) and abacavir led to viral load suppression below 400 copies/ml in 85% of patients by week 24 (intention to treat analysis) [3]. In a randomized controlled trial, treatment-naive patients with viral loads of less than 100 000 copies/ml, who received the combination form of zidovudine and lamivudine in addition to abacavir and placebo (thrice daily regime), demonstrated an equivalent virological response to a regime in which abacavir was substituted by indinavir [4]. Patients with high baseline viral loads responded less well in the abacavir group although improvements in CD4 cell counts were equivalent [4]. More recent data suggest that improved adherence to a two tablet twice a day triple nucleoside regime (with no placebo) resulted in equivalent virological and immunological response to an indinavir-based thrice-daily regime even at high baseline viral loads [5]. To date, trials of this triple nucleoside regime have excluded patients presenting with life-threatening complications of HIV infection or low CD4 cell counts (< 100 cells/mm³). As part of the expanded use programme we have used the co-formulated preparation of zidovudine, lamivudine and abacavir (Trizivir) in a number of antiretrovir-

al-naive patients, largely because of drug interactions, but also in view of the ease of administration for patients (one capsule twice a day).

A retrospective review of all patients with HIV-1 infection, naive to antiretroviral therapy and presenting with an AIDS-defining illness to our unit between October 2000 and April 2001 was performed. Patients who had received at least one dose of Trizivir and had a baseline CD4 cell count of less than 100 cells/mm³ or a viral load greater than 100 000 (5.0 log) were included. Age, sex, ethnicity and mode of transmission of HIV were recorded. Baseline and follow-up viral loads, CD4 cell counts, presenting and subsequent opportunistic infections, adverse events, clinical, virological and immunological outcomes were recorded for all patients.

A total of seven patients met the inclusion criteria. Of these, six received Trizivir as first-line therapy and one further patient (number 7, Table 1) received Trizivir within 2 weeks of the initiation of nevirapine/combivir, which had been discontinued because of liver toxicity. Patient characteristics at baseline are shown in Table 1. All presented with an AIDS-defining illness [three tuberculosis (one with concomitant cytomegalovirus encephalitis), one *Mycobacterium avium* complex infection, two *Pneumocystis carinii* pneumonia and one high-grade non-Hodgkin's lymphoma] and commenced Trizivir within one month of presentation. The median age was 37 years (range 26–60 years). At presentation the median viral load was 180 000 copies/mm³ (5.26 log) and in five the viral load was greater than 100 000 copies/mm³. The median CD4 cell count was 27 cells/mm³ and in six the CD4 cell count was below 100 cells/mm³.

Trizivir was well tolerated and no adverse effects were recorded. All patients have survived beyond 48 weeks and there have been no further opportunistic infections. All patients gained weight, with a median gain of 14 kg (3–22 kg) and all patients achieved an undetectable (< 80 copies/ml) viral load by 24 weeks. Six have had a sustained virological response to date (follow-up range 12–18 months). Median CD4 cell count increases were by 198 cells/mm³ (range 111–308 cell/mm³).

Virological failure occurred in patient 4; the initial viral

Table 1. Characteristics of patients before and after the initiation of Trizivir (zidovudine/lamivudine/abacavir).

Baseline characteristics of patients						Characteristics of patients at follow-up					
Patient	Age/sex	Ethnicity (transmission)	AIDS-defining condition	Concomitant medication	Viral RNA/mm ³ (log)	CD4 cell count	Follow-up (months)	Weight change (kg)	Viral RNA/mm ³ follow-up	CD4 cell count/mm ³ follow-up	Adverse events or opportunistic infections
1	32/M	African (heterosexual)	Disseminated MAC	Ethambutol, rifabutin, azithromycin, cotrimoxazole	1 800 000 (6.25 log)	27	17	+8	< 80	366	No
2	60/F	African (blood transfusion)	Tuberculosis, candidiasis	Rifater, ethambutol, cotrimoxazole	920 000 (5.96 log)	70	16	+12	< 80	378	No
3	58/M	European (homosexual)	Tuberculosis, candidiasis	Rifater, cotrimoxazole	120 000 (5.08 log)	14	18	+22	< 80	212	No
4	26/F	African (heterosexual)	CNS CMV, tuberculosis	Rifater, gancyclovir, cidofovir, cotrimoxazole	84 000 (4.92 log)	3	12	+20	24 000	137	No
5	51/M	European (homosexual)	High-grade lymphoma	Adriamycin, vincristine, cyclophosphamide, bleomycin, etoposide, cotrimoxazole	1 100 000 (6.04 log)	186	14	+3	< 80	445	No
6	33/M	European (not known)	PCP, hepatitis C	Pentamidine	28 000 (4.45 log)	60	16	+17	< 80	171	No
7	37/M	European (homosexual)	PCP	Cotrimoxazole, azithromycin	180 000 (5.26 log)	7	14	+14	< 80	186	No

CMV, Cytomegalovirus; CNS, central nervous system; MAC, *Mycobacterium avium* complex; PCP, *Pneumocystis carinii* pneumonia

load was 84 000 copies/mm³. By week 24 the viral load was recorded as less than 80 copies/mm³, but rebound to 2500 copies/mm³ occurred by week 36. The patient subsequently admitted to poor adherence to therapy. Genotypic resistance testing showed D67N, K70R and M184V reverse transcriptase codon mutations, with retained susceptibility to all protease inhibitors and non-nucleoside reverse transcriptase inhibitors. Despite virological failure, the patient achieved a sustained improvement in well-being, CD4 cell count (+134 cells/mm³), and further treatment options were not compromised. Two further patients have experienced viral load 'blips'. With patient 3 the viral load increased to 8400 copies/mm³ at the time of discontinuation of tuberculous therapy, but virological control was rapidly re-established without changing therapy. In patient 5, who presented with non-Hodgkin's lymphoma the baseline viral load was 1 100 000 copies/mm³ decreasing to less than 80 copies/mm³ by week 12. Viral load 'blips' of 710 and 230 copies/mm³ occurred at 6 and 7 months. Virological control was regained without recourse to an alteration in therapy and was sustained at 12 months.

Although these are clinical observations on a small number of patients, this does reflect our early experience of this new combination therapy in patients with advanced HIV infection. These clinical data add to clinical trial data in which such patients have been excluded because of low CD4 cell counts, opportunistic infections and potential drug interactions with comparator agents [3–5]. The data support the use of Trizivir in patients with a high viral load, low CD4 cell counts and opportunistic infections, particularly when there are concerns over pill burden and when there is the potential for serious drug–drug interactions. In particular, Trizivir may prevent further AIDS-related events and mortality in patients with tuberculosis and

low CD4 cell counts when commenced within the initial phase of antituberculous therapy, as has been shown for highly active antiretroviral therapy in general [6].

R. Andrew Seaton, Ray Fox, Neena Bodasing, S. Erica Peters and Ysobel Gourlay, Brownlee Centre, Gartnavel General Hospital, Glasgow G12 0YN, UK.

Received: 9 August 2002; revised: 22 August 2002; accepted: 3 September 2002.

DOI: 10.1097/01.aids.0000050829.06065.bb

References

1. Opravil M, Hirschel B, Lazzarin A, Furrer H, Chave JP, Yerly S, *et al.* A randomized trial of simplified maintenance therapy with abacavir, lamivudine and zidovudine in human immunodeficiency virus infection. *J Infect Dis* 2002, **185**:1251–1260.
2. Clumeck N, Goebel F, Rozenbaum W, Gerstoft J, Staszewski S, Montaner J, *et al.* Simplification with abacavir-based triple nucleoside therapy versus continued protease inhibitor-based highly active antiretroviral therapy in HIV-1 infected patients with undetectable plasma HIV-1 RNA. *AIDS* 2001, **15**: 1517–1526.
3. Kirkland LR, Fischl MA, Tashima KT, Paar D, Gensler T, Graham NM, *et al.* Response to lamivudine–zidovudine plus abacavir twice daily in antiretroviral-naïve, incarcerated patients with HIV infection taking directly observed therapy. *Clin Infect Dis* 2002, **34**:511–518.
4. Staszewski S, Keiser P, Montaner J, Raffi F, Gathe J, Brotas V, *et al.* Abacavir-lamivudine-zidovudine vs indinavir-lamivudine-zidovudine in antiretroviral-naïve HIV infected adults. *JAMA* 2001, **285**:1155–1163.
5. Vibhagool A, on behalf the CNA 3014 International Study Team. Abacavir/combivir is comparable to indinavir/combivir in HIV-1 infected antiretroviral therapy-naïve adults: results of the 48 week open label study (CNA 3014). In: *First International AIDS Society Conference on HIV Pathogenesis and Treatment*. Buenos Aires, Argentina, 8–11 July 2001 [Abstract 063].
6. Dean GL, Edwards SG, Ives NJ, Mathews G, Fox EF, Navaratne L. Treatment of tuberculosis in HIV-infected persons in the era of highly active antiretroviral therapy. *AIDS* 2002, **16**:75–83.

Reply to 'Different degree of immune recovery using antiretroviral regimens with protease inhibitors or non-nucleosides', by Barreiro *et al.*

Barreiro and colleagues [1] reported a significant immune recovery in patients undergoing treatment with a regimen of highly active antiretroviral therapy (HAART) including either a protease inhibitor (PI) or a non-nucleoside reverse transcriptase inhibitor. A rapid CD4 cell increase occurred shortly after beginning antiretroviral therapy. Late increases in CD4 cell counts, mostly as a result of newly produced cells rather than redistribution, were more pronounced in patients treated with PI, especially in individuals with lower initial CD4 cell counts.

Although the size of the study population was small, the authors affirmed that the greater immunological

benefit provided by PI might be related to some secondary properties of these compounds. In particular, they underlined the inhibition of the apoptosis of CD4 T cells, more relevant among patients with lower CD4 cell counts. Indeed, in patients with low CD4 cell counts there is a strong activation of CD4 cells as evaluated by the increased expression of markers of cell activation (CD38+HLA-DR+) and cell cycle (Ki67+) [2–4]. Therefore, the direct anti-apoptotic activity of PI might have a greater impact in patients with greater immune activation.

In our opinion another mechanism could also contribute to explain the better performance of PI among

patients with low CD4 cell counts. PI, through the mechanism of the inhibition of protease enzyme, can determine the production of non-replicative-competent HIV circulating in the blood stream. These viral defective particles maintain an antigenic stimulus on the immune system, potentially inducing both a cellular and a humoral immune response against HIV-1. In all 10 patients treated with a PI-including antiretroviral regimen, we demonstrated an increasing neutralizing antibody titre against autologous virus, not reported in the remaining 23 patients treated with a PI-sparing regimen [5]. In particular, a significant correlation among changes in the neutralizing antibody titre and variation in the CD4 cell count was observed. At week 52, only patients with an increased neutralizing antibody titre (fourfold or greater increase compared with pre-therapy titre) showed a significant decrease in viral load and higher CD4 cell count compared with pre-therapy values [5]. Furthermore, the presence of a relevant neutralizing antibody titre is frequently detected in patients with persistent and continuous antigenic stimulation such as occurs in patients with a high viral load and low CD4 cell count [6]. In these patients a significant linear correlation was found between neutralizing antibody titres and CD4 cell counts ($P = 0.001$, $r = 0.546$) but not with HIV-RNA levels in the plasma [6]. Therefore, in addition to the anti-apoptotic effect, the stimulation of the HIV-1-specific immune system, as assessed by the autologous neutralizing antibody titre, might have a relevant impact in

HIV-infected individuals with a more pronounced immune impairment.

Emanuele Nicastrì^a, Loredana Sarmati^b and Massimo Andreoni^b, ^aIstituto Nazionale per le Malattie Infettive, IRCCS Lazzaro Spallanzani, Rome, Italy; and ^bUniversity of Tor Vergata, Rome, Italy.

Received: 22 February 2002; accepted: 27 August 2002.

DOI: 10.1097/01.aids.0000050830.06065.6d

References

1. Barreiro P, Soriano V, Casas E, Gonzalez-Lahoz J. **Different degree of immune recovery using antiretroviral regimens with protease inhibitors or non-nucleosides.** *AIDS* 2002, **16**:245–249.
2. Deeks SG, Hoh R, Grant RM, et al. **CD4+ T cell kinetics and activation in human immunodeficiency virus-infected patients who remain viremic despite long-term treatment with protease inhibitor-based therapy.** *J Infect Dis* 2002, **185**:315–323; 329.
3. Fauci A. **Host factors and the pathogenesis of HIV-induced disease.** *Nature* 1996, **384**:529–534.
4. Meyaard L, Otto S, Jonker R, Mijster M, Keet R, Miedema F. **Programmed death of T cells in HIV-1 infection.** *Science* 1992, **257**:217–219.
5. Sarmati L, Nicastrì E, el-Sawaf G, et al. **Increase in neutralizing antibody titer against sequential autologous HIV-1 isolates after 16 weeks saquinavir (Invirase) treatment.** *J Med Virol* 1997, **53**:313–318.
6. Sarmati L, d'Etorre G, Nicastrì E, et al. **Neutralizing antibodies against autologous human immunodeficiency virus type 1 isolates in patients with increasing CD4 cell counts despite incomplete virus suppression during antiretroviral treatment.** *Clin Diagn Lab Immunol* 2001, **8**:822–824.

Resolution of azole-resistant oesophageal candidiasis in an AIDS patient after treatment with caspofungin

Sollima and co-workers [1] described a case of multi-drug-refractory oropharyngeal and oesophageal candidiasis in an HIV-infected individual with a good clinical response to caspofungin. Candidiasis is a frequently reported complication of HIV infection, but with the introduction of highly active antiretroviral therapy (HAART) its incidence has significantly declined. The increasing failure of HAART regimes does, however, mean that the treatment of multidrug-resistant candidiasis is becoming more problematical. We describe here an AIDS patient with intermittent oropharyngeal and oesophageal candidiasis of 5 years' duration, which became persistent and then severe and azole resistant.

The 38-year-old man had been followed at the Royal Free Hospital since 1999 and previously at St Bartholomew's Hospital, where he was diagnosed with HIV in 1992. He had had several AIDS-defining diseases, including refractory *Pneumocystis carinii* pneumonia, HIV encephalopathy and HIV myelopathy. The patient had failed several HAART regimens and was on multi-drug rescue therapy, including lopinavir, lamivudine, tenofovir and the fusion inhibitor T20. His CD4 cell

count at the time of caspofungin therapy was 3 cells/ μ l and his HIV-RNA level was 119 000 copies/ml.

The patient had suffered from recurrent bouts of oropharyngeal and oesophageal candidiasis since 1994. He had been treated with several courses of fluconazole, itraconazole and 5-flucytosine, before being given intravenous liposomal amphotericin B. Despite treatment with these agents (to which there was limited response), the candidiasis persisted with resultant dysphagia and odynophagia. Clinically, white plaques of *Candida* covered 80% of the oral mucosa. At the time of commencing caspofungin treatment, *Candida* species isolated from oral washings showed resistance to fluconazole MIC 95 μ g/l (normal range < 8–64 μ g/l), and itraconazole MIC 1.5 μ g/l (normal range < 0.125–1.0 μ g/l). The isolates showed some sensitivity to amphotericin B MIC 0.047 μ g/l (no established range) and 5-flucytosine MIC 0.125 μ g/l (normal range < 4–32.0 μ g/l); however, the *Candida* was clinically refractory to both drugs. In addition, after liposomal amphotericin treatment, the patient's renal function became severely deranged.

In July 2001, caspofungin treatment was started on a named patient basis, and the patient received the drug at an initial loading dose of 70 mg and then 50 mg a day intravenously. After 2 days of treatment with caspofungin the patient developed acute abdominal pain and vomiting and was diagnosed with acute pancreatitis by a raised serum lipase level and computed tomography scan. Caspofungin was discontinued empirically and liposomal amphotericin B commenced. The *Candida* that had cleared somewhat on caspofungin recurred during the period on amphotericin B, which was discontinued after 5 days, because of declining renal function. Two weeks later treatment with 50 mg a day caspofungin was instituted for one week, and after 4 days of treatment the oral lesions were markedly reduced and the patient reported improved swallowing and less dysphagia. The patient was treated with caspofungin on two further occasions for 7 days each with similar results. The patient eventually died after a cerebral vascular accident and general organ failure, but his death was thought to be unrelated to his candidiasis or caspofungin therapy.

Caspofungin, a member of the new class of antifungal drugs, the echinocandins, acts as a non-competitive inhibitor of beta (1,3)-D-glucan, an essential component of the cell wall of many filamentous fungi and yeasts [2]. Fungicidal activity *in vivo* and *in vitro* against *Candida* yeasts and *Aspergillus* has been demonstrated, including isolates with multiple transport mutations and those with acquired or intrinsic resistance to fluconazole, amphotericin B and 5-flucytosine [3]. A multicentre, double blind study indicated that caspofungin is effective in oesophageal candidiasis [4]. A clinical response, defined as a resolution of symptoms and a significant reduction in endoscopic lesions 14 days after completing therapy, was seen in 82.6% of patients. Of the trials conducted so far, caspofungin has shown good tolerability, with side-effects being typically mild and rarely leading to discontinuation [5]. The most commonly reported side-effects were fever, nausea, vomit-

ing and complications associated with the vein into which caspofungin was infused.

In conclusion, both the results of this case and the case reported by Sollima and co-workers suggest that for multidrug-refractory or azole-resistant candidiasis caspofungin represents a viable treatment option. Clearly more data are required on the long-term efficacy and side-effects of the drug. In this patient pancreatitis occurred at the first treatment with caspofungin, but with subsequent treatments no adverse events were recorded. The clinical response to caspofungin was, however, marked and we believe that this drug may be of great benefit for HIV-infected patients with multidrug-resistant candidiasis.

Kate Smith, Mike Youle, Bob Baker, Jayne Ballinger, Zoe Cuthbertson and Margaret Johnson, Royal Free Centre for HIV Medicine, London, UK.

Received: 8 August 2002; accepted: 19 August 2002.

DOI: 10.1097/01.aids.0000050831.06065.24

References

1. Sollima S, Corbellino M, Cicconi P, Piazza M, Vigano O, Antinori S. Resolution of multidrug-refractory oesophageal candidiasis in an AIDS patient after treatment with caspofungin. *AIDS* 2002, **16**:1303–1304.
2. Maertens JA, Boogaerts MA. Fungal cell wall inhibitors: emphasis on clinical aspects. *Curr Pharmaceut Design* 2000, **6**:225–239.
3. Kontoyiannis DP, Lewis RE. Antifungal drug resistance of pathogenic fungi. *Lancet* 2002, **359**:1135–1141.
4. Villanueva A, Arathoorn EG, Gotuzzo E, Berman RS, DiNubile MJ. A randomised double-blind study of caspofungin versus amphotericin for the treatment of candidal esophagitis. *Clin Infect Dis* 2001, **33**:1529–1535.
5. Arathoorn EG, Gotuzzo E, Noriega LM, Berman RS, DiNubile MJ, Sable CA. Randomised, double-blind, multicenter study of caspofungin versus amphotericin B for treatment of oropharyngeal and esophageal candidiasis. *Antimicrob Agents Chemother* 2002, **46**:451–457.

***Salmonella typhimurium* prostatic abscess: a rare cause of persisting dysuria in an AIDS patient**

HIV-positive and AIDS patients are liable to acquire opportunistic infections [1], which can also include the urogenital system [2]. We report the first case of a prostatic abscess in an AIDS patient after an infection of the urinary tract with *Salmonella typhimurium*.

Case report

A 33-year-old homosexual man presented with complaints of dysuria, alguria, fatigue and persistent diarrhoea for several weeks. Examination revealed a

10 × 12 cm brown-red maculopapular lesion in the bilateral inguinal region. Biopsy confirmed the diagnosis of Kaposi's sarcoma. On presentation, the HIV test was positive, leukocytes were 4.08/μl. The CD4:CD8 cell ratio was 0.3 (normal > 0.9) with CD3/CD4 helper cells 17.1% (normal range 28–50%) and CD8 T suppressor cells 63.8% (normal range 22–40%). A computerized tomography scan revealed multiple paratracheal and mediastinal lesions consistent with manifestations of Kaposi's sarcoma.

Routine urine culture grew *S. typhimurium*, at a concentration greater than 10⁵/ml. Treatment with

ciprofloxacin 500 mg twice a day by mouth was initiated, and further infections with tuberculosis, pneumocystis, toxoplasmosis and cytomegalovirus were excluded. Three weeks after his first admission dysuria persisted despite antimicrobial treatment. As an area of the prostate showed contrast enhancement on the computerized tomography scan (Fig. 1), the patient was referred to the Department of Urology for further diagnosis and treatment.

On digital rectal examination a fluctuant, painful region in the right prostatic lobe was palpable. On transrectal ultrasound (TRUS) a 35 × 20 × 20 mm abscess was detected, which filled almost all of the right prostatic lobe. Using ultrasound guidance and local anaesthesia an 8 French pigtail drainage catheter was placed transperineally into the abscess cavity. Microbiology of the prostatic aspiration material also revealed *S. typhimurium*. The drain was left in place for 5 days and the abscess cavity was flushed once a day with a mixture of povidone-iodine/normal saline. The drainage decreased and symptoms resolved quickly. A normal TRUS was seen 5 days after the initiation of therapy and the drain was removed. No re-infection occurred, the prostate appeared normal on TRUS and on digital rectal examination during follow-up.

Discussion

This is the first description of a prostatic abscess caused by *S. typhimurium* in an AIDS patient. In the pre-antibiotic era, prostatic abscesses were known to be associated mainly with *Neisseria gonorrhoeae*. The spectrum of organisms infecting the prostate has changed over the years, with 'common' urological bacteria now being the most prominent in prostatic infections. Nevertheless, HIV-positive and AIDS patients are particularly prone to any kind of infectious disease, and salmonella-related urinary tract infections are found in a significant number of these patients [1,2]. Whenever an HIV-positive or AIDS patient complains of urinary symptoms, the urologist must exclude prostatic involvement, such as acute prosta-

Mitochondrial DNA and sperm quality in patients under antiretroviral therapy

Antiretroviral therapy (ART) decreases HIV-associated morbidity and mortality by reducing viral concentrations in plasma, and may also decrease HIV transmissibility by decreasing viral shedding in the semen [1]. In seminal plasma, some nucleoside analogue reverse transcriptase inhibitors (NRTI; zidovudine, didanosine and lamivudine) have been identified in high concentrations, whereas others (abacavir) were found to be rapidly cleared from the male genital tract [2,3]. Recently, several side-effects of ART have been

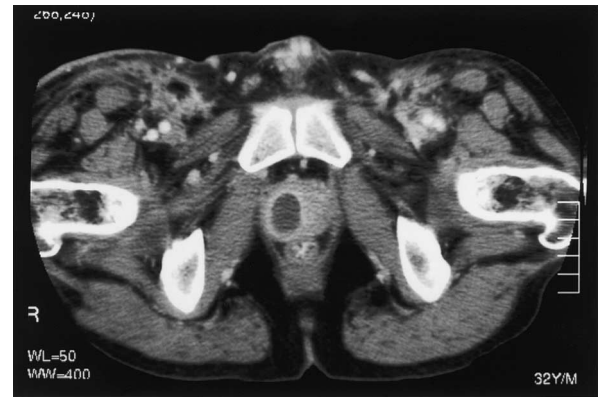


Fig. 1. Computerized tomography shows the abscess in the right lobe of the prostate.

titis or a prostatic abscess. Recommendations regarding the treatment of prostatic abscesses include perineal drainage and transurethral resection [3]. We believe that the perineal approach carries fewer side-effects such as retrograde ejaculation, which is particularly bothersome to younger patients. It is well tolerated and leaves the option of repeatedly flushing the abscess area.

Markus Giessing, Egbert Baumgart, Severin Lenk and Stefan A. Loening, Department of Urology, Charité University Hospital, Berlin, Germany.

Received 13 August 2002; accepted: 3 September 2002.

DOI: 10.1097/01.aids.0000050833.06065.b6

References

- Schonwald S, Begovac J, Skerk V. **Urinary tract infections in HIV disease.** *Int J Antimicrob Agents* 1999, 5:309–311.
- Gruenewald R, Blum S, Chan J. **Relationship between human immunodeficiency virus infection and salmonellosis in 20- to 59-year-old residents of New York City.** *Clin Infect Dis* 1994, 18:358–363.
- Trauzzi SJ, Kay CJ, Kaufman DG, Lowe FCL. **Management of prostatic abscess in patients with human immunodeficiency syndrome.** *Urology* 1994, 43:629–633.

associated with the prolonged use of NRTI and their ability to inhibit polymerase gamma, the enzyme responsible for the replication of mitochondrial DNA. Decreased mtDNA levels have been identified in the subcutaneous adipose tissue of patients suffering from HIV-associated lipodystrophy [4], and it has been suggested that mtDNA levels in the blood might be employed to monitor this form of toxicity [5]. A functionally intact mitochondrial genome is also pivotal to sperm motility [6,7]. Any toxic effect of ART on

sperm quality may have important clinical implications with regard to the fertilization technique, as artificial insemination with motile, virus-free spermatozoa prepared from HIV-infected men is used in HIV-discordant couples wishing to conceive.

We performed a cross-sectional study to investigate whether mtDNA depletion resulting from long-term NRTI use might be identified in the seminal compartment. We explored whether such a depletion might be associated with a reduced quantity or quality of sperm.

Semen samples were collected after at least 4 days of sexual abstinence from 31 consecutive HIV-positive patients willing to give written informed, ethics committee-approved, consent. At the time of semen collection, 24 HIV patients were receiving ART and seven were not (five ART-naïve). An additional seven HIV-negative individuals with normal mobility were analysed. After liquefaction, the sperm count and motility was recorded according to WHO standards. Genomic DNA was extracted from an aliquot of the ejaculate and mtDNA was quantified using a Southern blot technique [4].

There was no statistical difference with regard to the mtDNA content and sperm characteristics (sperm count, motility) between HIV patients receiving ART, HIV patients without ART, or HIV-negative individuals. The sperm count, sperm motility and mtDNA content varied widely within all groups, the standard deviation of the means being in the order of 50, 30 and 50%, respectively. 'D' drugs consisting of didanosine (ddI), zalcitabine (ddC) and stavudine (d4T) are thought to be relatively strong inhibitors of mtDNA replication, but there was no statistical difference with regard to the sperm count, sperm motility and mtDNA content when the HIV-positive patients were divided into a subgroup ($n = 19$) currently receiving any of the 'd' drugs and a subgroup not currently receiving 'd' drugs ($n = 12$). However there was a weak negative correlation between the time on 'd' drugs with the mtDNA content ($P = 0.04$, $r = 0.44$). None of the groups and subgroups differed with regard to the CD4 cell count and viral load (when applicable). MtDNA deletions were never observed.

Our study may have a number of limitations. Seminal fluid contains cells other than spermatozoa, and an influence of these sperm components on our measurements cannot be ruled out. We observed epithelial cells

in a relative frequency of up to 20% in some of our samples, and these cells are likely to harbour higher copy numbers of mtDNA per cell than spermatocytes. The stage of HIV disease itself may also have an influence on sperm function, as a correlation between the CD4 cell count and sperm motility has been identified by others [8]. Finally, an effect of ART on sperm count, sperm motility and mtDNA content may have been obscured by the high interindividual variability of the parameters in each group. We conclude that sperm does not appear to be useful in monitoring mitochondrial toxicity, but that longitudinal studies are prudent to rule out the potential adverse effects of ART on the reproductive tract.

Susanne Diehl^a, Pietro Vernazza^b, Andreas Trein^c, Eiko Schnaitmann^c, Bodo Grimbacher^a, Bernhard Setzer^a and Ulrich A. Walker^a, ^aMedizinische Universitätsklinik, Department of Rheumatology and Clinical Immunology, Freiburg, Germany; ^bKantonsspital, St Gallen, Switzerland; and ^cHIV-Practice, Stuttgart, Germany.

Received: 9 August 2002; accepted: 3 September 2002.

DOI: 10.1097/01.aids.0000050834.06065.78

References

- Barroso PF, Schechter M, Gupta P, Melo MF, Vieira M, Murta FC, et al. **Effect of antiretroviral therapy on HIV shedding in semen.** *Ann Intern Med* 2000, **133**:280–284.
- Gatti G, Bonora S, Liuzzi G, Guaraldi G, Bucci B, DePascalis CR, et al. **DDI concentrations in seminal plasma.** In: *8th European Conference on Clinical Aspects and Treatment of HIV Infection.* Athens, 28–31 October 2001, p. 157.
- Kashuba AD, Dyer JR, Kramer LM, Raasch RH, Eron JJ, Cohen MS. **Antiretroviral-drug concentrations in semen: implications for sexual transmission of human immunodeficiency virus type 1.** *Antimicrob Agents Chemother* 1999, **43**:1817–1826.
- Walker UA, Bickel M, Lütke Volksbeck SI, Ketelsen UP, Schofer H, Setzer B, et al. **Evidence of nucleoside analogue reverse transcriptase inhibitor-associated genetic and structural defects of mitochondria in adipose tissue of HIV-Infected patients.** *J Acquir Immune Defic Syndr* 2002, **29**:117–121.
- Cote HC, Brumme ZL, Craib KJ, Alexander CS, Wynhoven B, Ting L, et al. **Changes in mitochondrial DNA as a marker of nucleoside toxicity in HIV-infected patients.** *N Engl J Med* 2002, **346**:811–820.
- Folgero T, Bertheussen K, Lindal S, Torbergsen T, Oian P. **Mitochondrial disease and reduced sperm motility.** *Hum Reprod* 1993, **8**:1863–1868.
- Ruiz-Pesini E, Diez C, Lapena AC, Perez-Martos A, Montoya J, Alvarez E, et al. **Correlation of sperm motility with mitochondrial enzymatic activities.** *Clin Chem* 1998, **44**:1616–1620.
- Dondero F, Rossi T, D'Offizi G, Mazzilli F, Rosso R, Sarandrea N, et al. **Semen analysis in HIV seropositive men and in subjects at high risk for HIV infection.** *Hum Reprod* 1996, **11**:765–768.

Efavirenz-induced psychosis leading to involuntary detention

Several drugs for treating somatic disorders may cause psychosis, and it is important to remember this, especially in patients with a strong disposition to mental

illness. Suspicion of drug-induced mental illness should be raised in psychotic patients who do not have any history of mental disorder.

HIV infection and AIDS can be associated with mental illness. The first manifestation of an HIV infection may include acute schizophrenia-like psychosis and mania leading to involuntary commitment [1], and new-onset psychosis in already diagnosed HIV-infected patients has been described in detail [2,3]. Such cases have been related to HIV-related encephalopathy.

Only a few reports on drugs used in the treatment of HIV and AIDS leading to psychosis have been published. The current recommendation for treating HIV infections is a combination of a nucleoside reverse transcriptase inhibitor with either a non-nucleoside reverse transcriptase inhibitor or a protease inhibitor [4].

Efavirenz is a relatively newly introduced non-nucleoside reverse transcriptase inhibitor, and so far only a few cases of psychosis have been described in connection with this drug [5,6]. Symptoms included paranoid delusions, confusion, insomnia, and overdose mania. To avoid making erroneous associations between a drug and a possible side-effect of psychosis requires a thorough psychiatric assessment [7].

A 40-year-old male homosexual nurse was referred to the psychiatric clinic because of suicidal thoughts, and after having cut his wrist superficially with a knife. The patient had not been admitted to any psychiatric ward before, but had had mood fluctuations and had therefore been treated with an unknown antidepressant for a couple of years, but had stopped taking this drug several months before being referred. He had a strong disposition to bipolar disorder because his brother, mother and possibly grandmother all suffered from bipolar disorder. He had no history of mania, hypomania, alcohol or drug abuse. He was physically fit except for his HIV infection.

The patient's HIV infection was diagnosed in 1988, and he had been compliant with the treatment for his illness.

Four weeks before admission he had no signs of HIV-related encephalopathy, and his CD4 cell count was good (0.00067 cells/mm³) with signs of low viraemia (244 copies HIV RNA). At this time his medical treatment had not been changed for several months, and consisted twice a day of a combination of 150 mg lamivudine and 300 mg zidovudine, indinavir 800 mg and ritonavir 100 mg. Efavirenz at 600 mg a day was added for 4 weeks, after which the patient developed suicidal thoughts and paranoid delusions of being kept under surveillance by a computer and through hidden microphones installed in his radiator. Furthermore, he experienced having his brother's thoughts in his head, and hearing voices speaking to him. His mood was severely depressed. The patient had no insight and tried to leave the ward, so a decision to detain the patient

involuntarily was taken as a result of his being severely psychotic and suicidal.

The acute blood tests were normal except a slightly increased lactate-dehydrogenase level. The next day the efavirenz treatment was discontinued on the basis of a possible drug-induced psychosis, and after 2 days the symptoms were almost gone, and the patient was discharged.

This case shows an example of an acute, severe psychosis presenting with paranoid delusions, suicidal thoughts, depressed mood, auditory hallucinations, and schizophrenia-like first-rank symptoms of thought insertion. The patient's psychosis was so severe that he was involuntarily detained. There was a clear association with the efavirenz treatment and the development of psychosis. When efavirenz was discontinued, the psychotic symptoms disappeared. The patient showed no signs of an HIV-related encephalopathy, and if this had been the case, one would expect the psychotic symptoms to persist for a longer time, and not to disappear so quickly without any anti-psychotic treatment.

An important issue is the patient's strong disposition to bipolar disorder. Among first relatives of bipolar patients the risk of inheriting the disease is more than 20% [8]. The patient had a history of mood fluctuations, and had been treated with an antidepressant. No history of mania or hypomania was evident. The psychotic symptoms included symptoms from both the affective and schizophrenic spectrum. This is often the case in drug-induced psychosis presenting an 'unclear' picture [9]. If a drug is known to induce psychosis, extra care should be taken before prescribing it to individuals with a disposition to mental disorder.

As psychotic symptoms do not seem to occur infrequently in patients with HIV and AIDS, physicians treating these patients should include a brief psychiatric interview as an addition to the regular medical examination.

Henrik Day Poulsen and Henrik K. F. Lublin, *Psychiatric Clinic O, H:S Rigshospitalet, Copenhagen University Hospital, 2100 Copenhagen Ø, Denmark.*

Received: 24 July 2002; revised: 22 August 2002; accepted: 3 September 2002.

DOI: 10.1097/01.aids.0000050835.06065.31

References

1. Röttgers HR, Weltermann BM, Evers S, Husstedt IW. **Psychia-**

- trische Akutsymptomatik als Erstmanifestation einer HIV-infection.** *Der Nervenarzt* 2000, **71**:404–410.
- Harris MJ, Jeste DV, Gleghorn A, Sewell D. **New-onset psychosis in HIV-infected patients.** *J Clin Psychiatry* 1991, **52**:369–376.
 - Halstead S, Riccio M, Harlow P, Oretti R, Thompson C. **Psychosis associated with HIV-infection.** *Br J Psychiatry* 1988, **153**: 618–623.
 - Carpenter CCJ, Fischl MA, Hammer SM, Hirsch MS, Jacobsen DM, Katzenstein DA, et al. **Antiretroviral therapy for HIV infection in 1998: updated recommendations of the International AIDS Society USA panel.** *JAMA* 1998, **280**: 78–86.
 - Garza CLS, Duarte SP, Garcia-Martin C, Gutierrez-Casares JR. **Efavirenz-induced psychosis.** *AIDS* 2001, **15**:1911–1912.
 - Blanch J, Corbella B, Garcia F, Parellada E, Gatell JM. **Manic syndrome associated with efavirenz overdose.** *Clin Infect Dis* 2001, **15**:270–271.
 - Gonzalez A, Everall I. **Efavirenz-induced psychosis –reply.** *AIDS* 1999, **13**:1996.
 - Goodwin FK, Jamison KR. *Manic-depressive illness.* New York: Oxford University Press; 1990.
 - Kaplan HI, Sadock BJ, Sadock VA. *Comprehensive textbook of psychiatry*, 7th ed. New York: Lippincott Williams and Wilkins; 2000.